A black silhouette of a person's head and shoulder is positioned on the left side of the slide. Overlaid on the shoulder area is a diagram showing the skeletal structure of the shoulder joint. A curved arrow indicates the range of motion or the direction of the dislocation. The text is centered over the right side of the silhouette.

SURGICAL MANAGEMENT OF ACUTE (FIRST TIME) SHOULDER DISLOCATION (AFTSD)

Jai Relwani

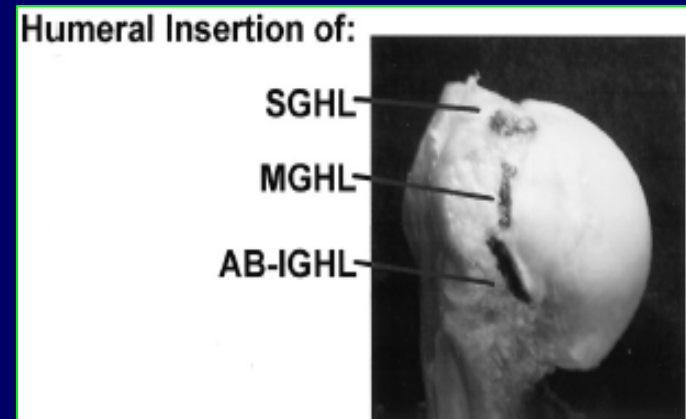
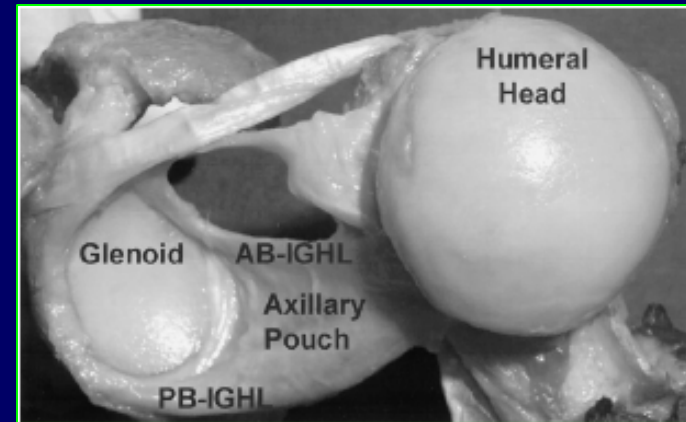
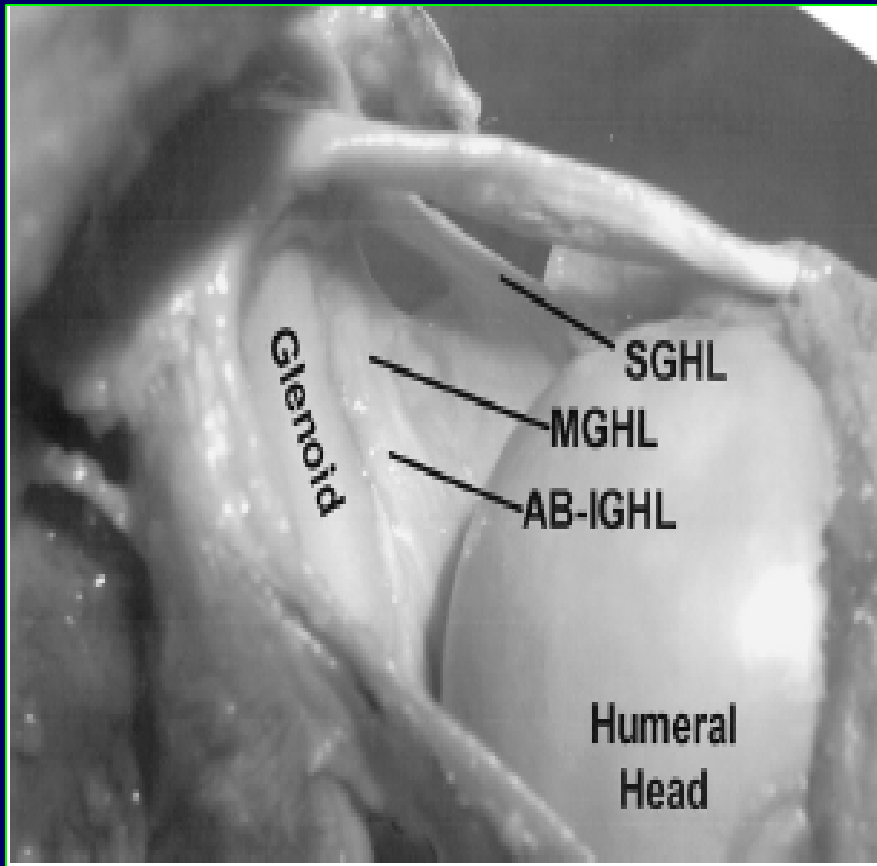
Reading Shoulder Unit, Reading, UK

- **What is the problem?**
- **Who Are We Talking About?**
- **Why Do We Need To Talk About It?**
- **Do We Have A Good Answer?**
- **Is It Arthroscopy (as usual)?**

What is the Problem?.....

Anterior shoulder dislocation is the commonest dislocation in the human body with an incidence of 1-2% in the general population.

Glenohumeral Ligaments



Force On GH Ligaments in Various Degrees of Abduction

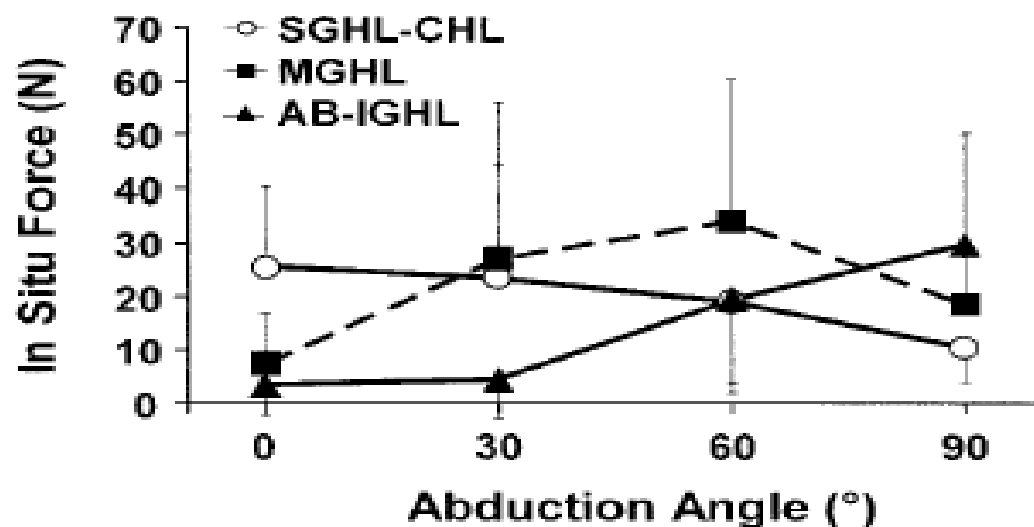
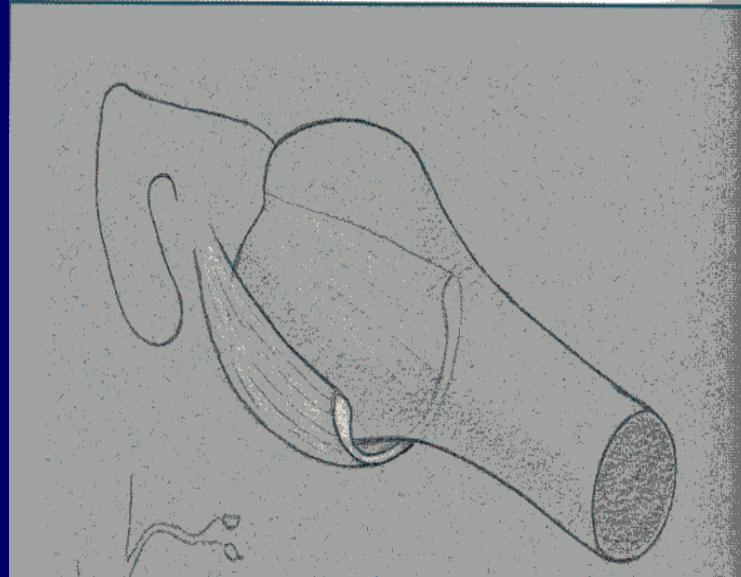


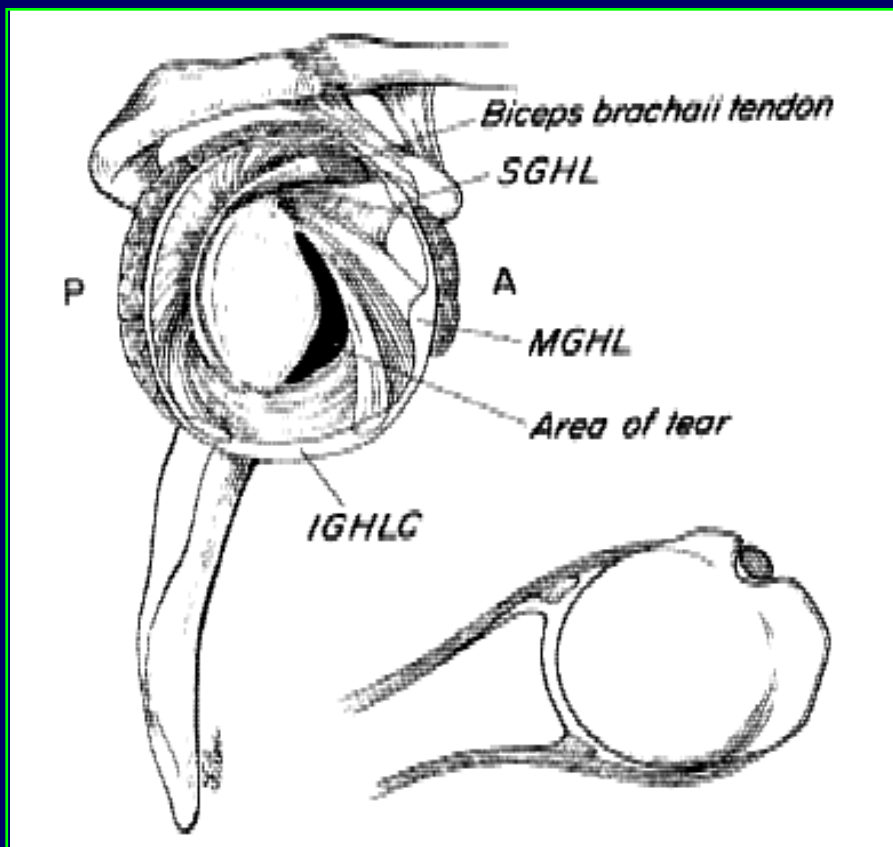
Fig 6. In situ force (mean \pm standard deviation) in the glenohumeral ligaments with an anterior load of 89 N applied to the glenohumeral joint is shown. SGHL-CHL = superior glenohumeral and coracohumeral ligament complex; MGHL = middle glenohumeral ligament; AB-IGHL = anterior band of the inferior glenohumeral ligament

No one structure stabilizes the Glenohumeral Joint throughout the range of motion



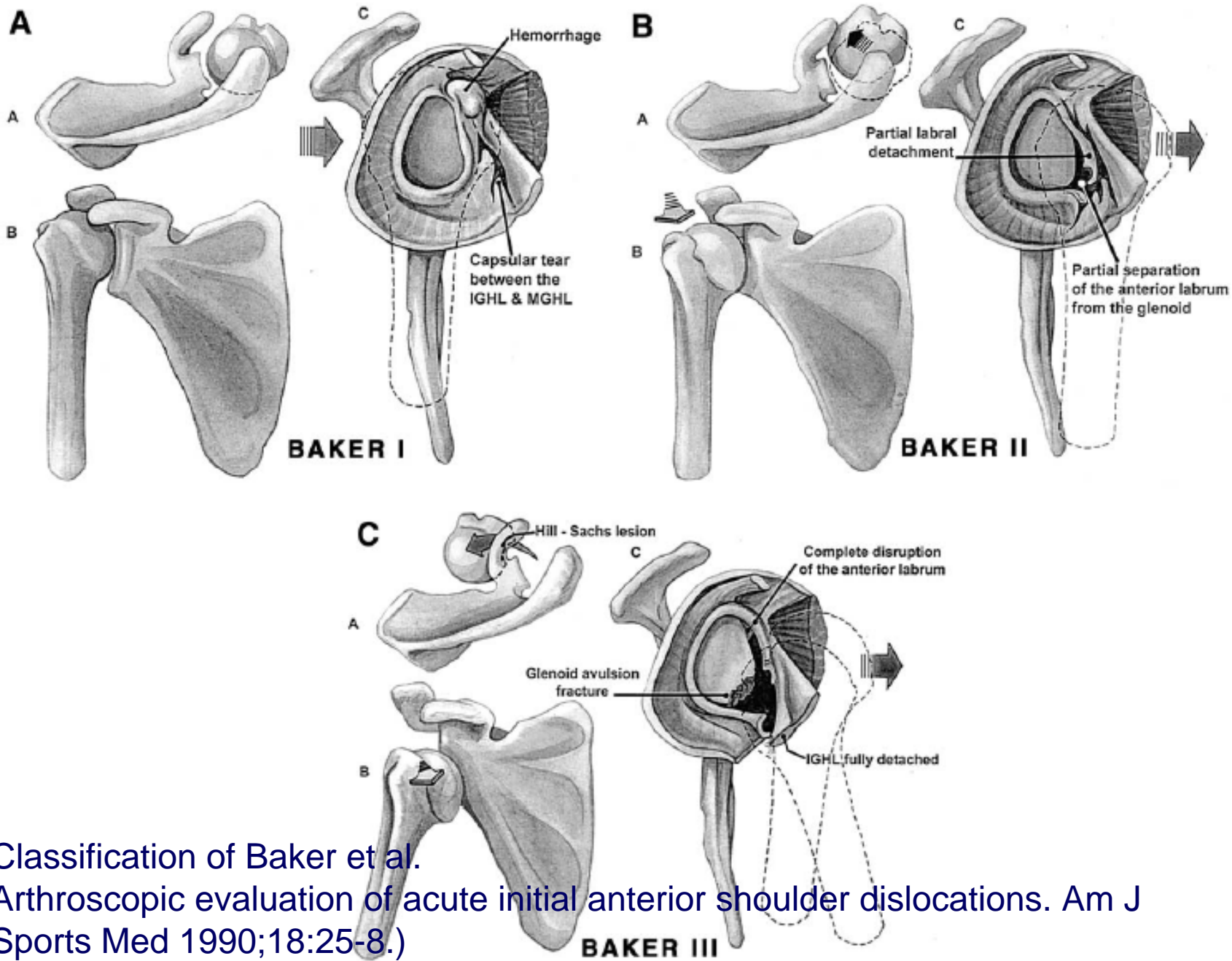
The Inferior Glenohumeral ligament complex was found to be the most important stabilizer against antero-inferior shoulder dislocation- IGHL Hammock

The Bankart – Perthe Lesion



- Present in 97% cases of acute traumatic dislocation.

Classification of Baker et al.
Arthroscopic evaluation of acute
initial anterior shoulder dislocations.
Am J Sports Med 1990;18:25-8.)



Classification of Baker et al.
 Arthroscopic evaluation of acute initial anterior shoulder dislocations. Am J Sports Med 1990;18:25-8.)

Classification/s

I. Degree of Instability

- Dislocation
- Subluxation

Classification/s

- **II. Number of Events**
- Acute
- Recurrent

Classification/s

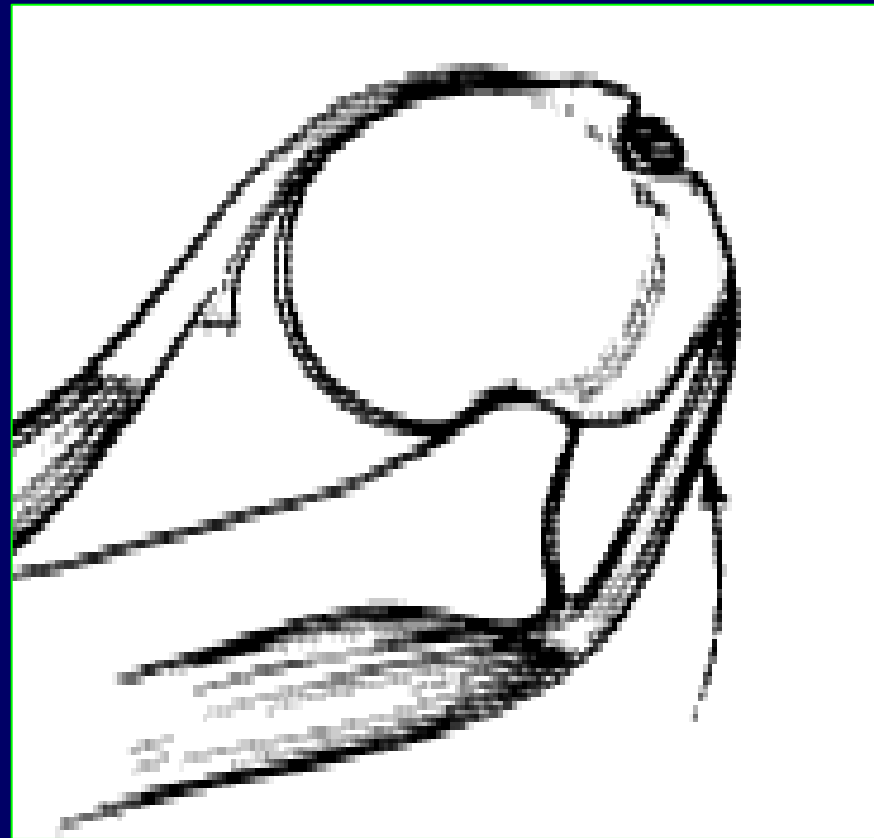
- **III. Etiology**
- Traumatic
- Atraumatic
- Neuromuscular
- Microtrauma

Classification/s

- **IV. Direction**
- **Unidirectional**
 - Anterior
 - Posterior
 - Inferior
- **Multidirectional**

Management of Acute Traumatic First Time Shoulder Dislocation

- **Dislocation**
- **Acute**
- **Traumatic**
- **Anterior**



Copyright Reading Shoulder Unit,
UK

Who Are We Talking About?

Copyright Reading Shoulder Unit,
UK

Recurrence Rate

- Activity Level
- Age

Recurrence Rate

McLaughlin and MacLellan (12) compared 256 recurrent dislocations with 315 primary dislocations.

- Ninety-six percent of patients with recurrent dislocation sustained their initial dislocation when they were younger than 30 years of age, whereas of the 315 cases of nonrecurrent dislocation, 90% occurred in patients older than 30 years.

Rowe (13) similarly found a recurrence

- rate of 94% in 53 patients younger than 20 years of age,
- 79% in 64 patients 21 to 30 years of age, 50% in 16 patients 31 to 40 years of age, and 14% in 188 patients older than 40.

Recurrence - Age

- McLaughlin and MacLellan

Dislocation	Age <30	Age >30
Recurrent (n=256)	96%	10%
Nonrecurrent (n=315)	10%	90%

McLaughlin HL, MacLellan DI. Recurrent anterior dislocation of the shoulder II. A comparative study. *J Trauma* 1967;72:191–201.

Recurrence - Age

Rowe et al

AGE	Recurrence
<20 yr	94%
21-30	79%
31-40	50%
>40 yrs	14%

Rowe CR, Sakellairdes HT. Factors related to recurrences of anterior dislocation of the shoulder. *Clin Orthop* 1961;20:40–8.

Recurrence Rate –Age/Activity

- Simonet '84
 - 66% < 20 y/o
 - Athletes 82% < 30 y/o
 - Non-Athletes 30% < 30 y/o

Recurrence Rate – Age

< 25 y/o

- Arciero '94
- Henry '82
- Hovelius '78, '83, '87
- McLaughlin '67
- Rowe '80
- Simonet '84
- Wheeler '89

- **60-94% recurrence**

Acute Dislocation in Children

- 21 Patients
- Age 4 + 11 16 y/o
- F/U 7 m. - 165 m. (av. 6.5 y.)

Marans et al '92

Acute Dislocation in Children

- Recurrence - 100%
- Rx Had No Impact on Recurr.
- Av. Time to 1st Recurr. - 8 m.
- ER Loss 10-50°

Marans et al '92

Why Do We Need to Talk About It ?

Why Do We Need To Talk About It?

- Findings at the time of surgery
- Outcomes with “traditional” rx.

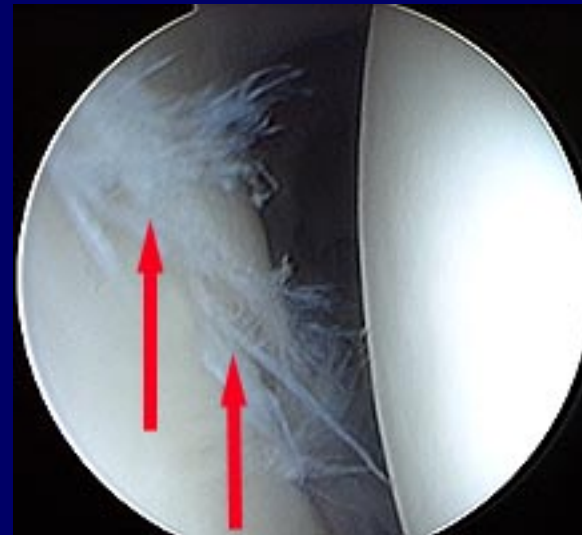Findings Of Primary Dislocation

Norlin '93

27 Patients

Avg. Age 22 (17-60)

- Hemarthrosis 100%
- Labral Damage 100%
- Bankart Lesion 100%
- Hill-Sachs 100%



West Point Experience

Findings

- Bankart Lesion 97%
- Hill-Sachs Lesion 90%
- HAGL Lesion 2%
- Hemarthrosis 100%

Primary Dislocation Findings

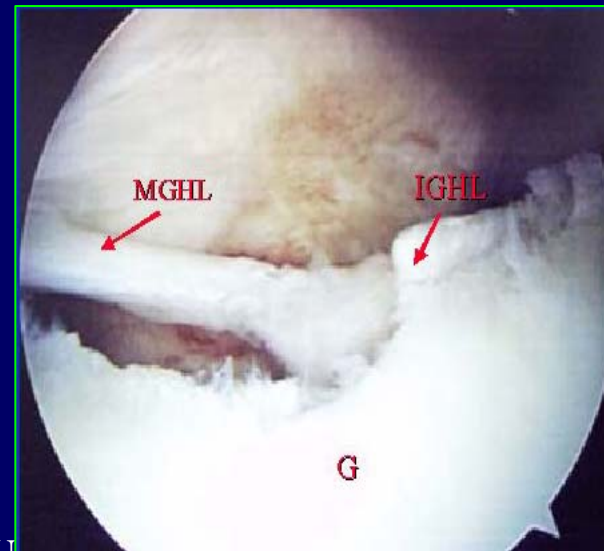
- Baker et al '90
 - 57 Pts.
 - No Previous Hx.
 - < 30 y/o
 - Traumatic

Arthroscopic Findings After 1° Dislocation

Author/s	Bankart lesion
Baker	87%
West Point	97%
Norlin	100%

No one who has ever seen this typical lesion exposed at operation could possibly doubt that the only rational treatment is to reattach the glenoid ligament to the bone from which it has been torn.”

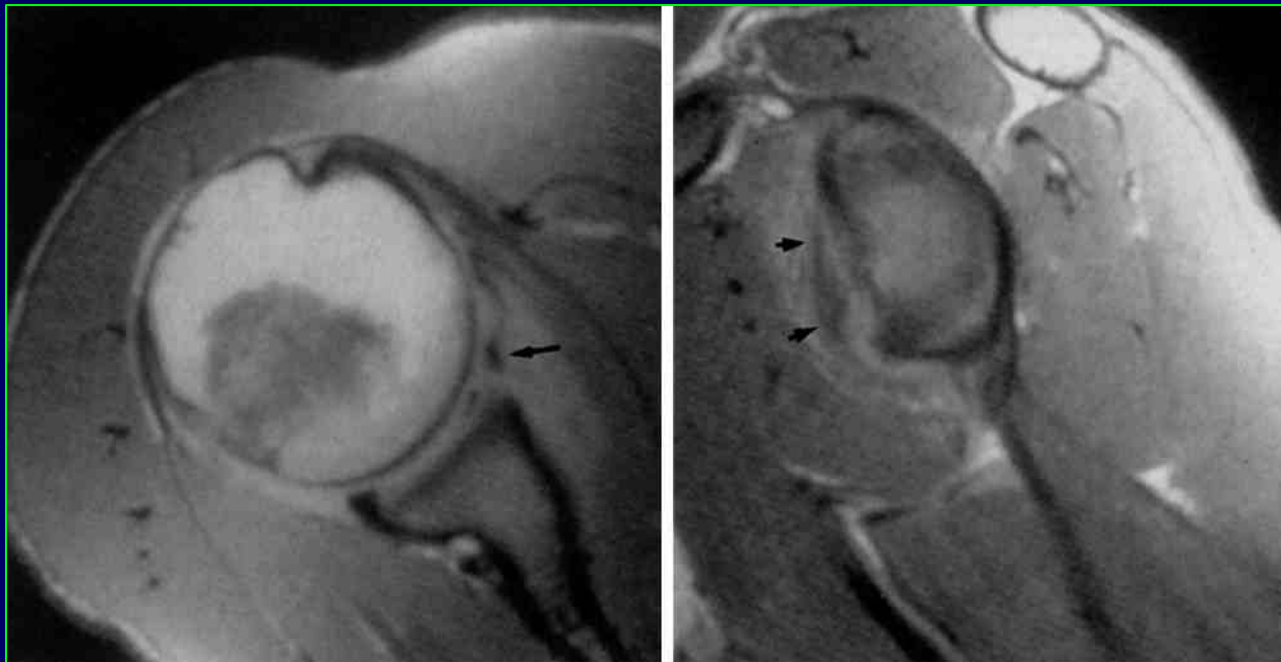
Bankart, Cantab 1923



Copyright Reading Shoulder Unit,
UK

Can MRI Give The Answers With Acute Dislocation?

- MRI Only “Moderately” Reliable for Acute Dislocation **Suder et al '95**



Copyright Reading Shoulder Unit,
UK

Can MRI Give The Answers With Acute Dislocation?

Agreement Between Magnetic Resonance Imaging and
Arthroscopic Evaluation of the Shoulder Joint in Primary
Anterior Dislocation of the Shoulder

Alexandra Kirkley et al, *Clinical Journal of Sport Medicine*, 13:148–151© 2003

- There was perfect agreement for the detection of Bankart lesions or equivalent capsulo-labral disruption, and also for Hill Sacks lesions.
- Mild to moderate agreement for other soft tissue lesions.

Do We Have A Good Answer ?

Copyright Reading Shoulder Unit,
UK

Non-Operative Rx of Acute Anterior Dislocation

Hovelius et al '96 : Primary Anterior Dislocation of the Shoulder in Young Patients: A Ten-Year Prospective Study

- 245 Patients
- 10 y. Follow-Up
- Age 12-40 y/o
- 3 Groups (Length/Type of Immobilization)
(immobilization with the arm tied with a bandage to the torso for three to four weeks after reduction of the dislocation/ use of a sling, which was discontinued after the patient was comfortable/ or immobilization for various durations)

Non-Operative Rx of Acute Anterior Dislocation

- 52% no recurrence.
- 4% single recurrence.
- 43% multiple recurrences
 - 23% surgical stabilization (58 cases).
 - 20% no surgery (recurrences in the 2-5 yr F/U, which stopped after 5 years)

Non-Operative Rx of Acute Anterior Dislocation

West Point Experience

- 127 Patients
- 55 Rx-Non-op
- 85% Recurrence

DeBarardino '96

Incidence of Arthropathy – 10 yrs

Hovelius et al

- Mild : 11%
- Mod./ Sev. : 11%
- Moderate/ Severe : 9%

- Some of the shoulders with arthropathy had never had a recurrence.

Factors That Don't Seem to Affect Recurrence Rate

- Type or Duration of Immobilization
- Rehabilitation
- Time to RTF

Immobilization : Ext Rotation OR Internal Rotation

Itoi et al

- Randomized, prospective, clinical study.
- Patients with an initial anterior shoulder dislocation were randomised to treatment with immobilization in either internal or external rotation for three weeks.
- 6/20 redislocations in IR
- 0/20 redislocations in ER

Results of Surgical Treatment

Ambacher, Paar '99

- 1° Dislocation/ Open Reconstruction
- 15 Patients
- F/U Average 2.5 y
- One Recurr. (7%)
- 10 Same Sp. Level
- > 50% Pts. w/ ER Loss < 10°

Recurrence Rates

Author	Non Surgical (Recurrence)	Surgical (Recurrence)
Wheeler '89	92%	22%
Arciero et al '94	80%	14%
Arciero et al '95		10%
Bottoni et al	75%	11.1%

Open vs Arthroscopic surgery

Copyright Reading Shoulder Unit,
UK

- Is The Answer Arthroscopy
(as usual)?

Scope vs Open

Study	No. of Patients*	Mean Duration of Follow-up* (mos.)	Recurrence Rate* (percent)
Field et al. (1999) ¹⁶	50/50	33/30	8/0
Steinbeck and Jerosch (1998) ³³	30/32	36/40	17/5
Guanche et al. (1996) ²²	25/12	27/25	33/8
Geiger et al. (1997) ¹⁷	16/18	23/34	43/0

*Arthroscopic stabilization/open stabilization.

Scope vs Open Surgery - Results

Metcalf (meta-analysis)

	Open	Arthroscopic
Redislocation rate	8%	9%
Avg. ER loss	11%	2%
Good/Exc. results	91%	92%

Copyright Reading Shoulder Unit,
UK

How Do You Measure Success?

- Recurrence
- ROM
- RTF
- Patient Satisfaction

ER Loss

Geiger et al '92

- Open 2x Greater Than Scope
- Scope $< 5^\circ$

Aspen Experience

- Open 25°
- 90° Abd./ Supine

Scope vs. Open Reconstruction

Scope Advantages

- OR Time
- No Damage to Subscap.
- Better Visualization
- Bld. Loss
- Morbidity
 - less pain
 - fewer narcotics
 - faster RTW/F
- Cosmesis
- Motion (Ext. Rot.)

Scope vs. Open

Scope Disadvantages

- Tech. Demanding
- Limited Applications
- Recurr. Rate 

ARAD vs. Closed Rx of Acute Dislocation

- **40 Patients**
- **< 30 y/o**
- **Prospective**
- **Randomized**
- **Transglenoid Tech**
- **Same Rehab.**
- **F/U > 24 m.**

Kirkley et al '99

ARAD vs. Closed Rx of Acute Dislocation

- **Recurrence**

ARAD 16%

Closed 47%

- **Quality of Life (WOSI)**

ARAD > Closed

- **ROM**

ARAD = Closed

Kirkley et al '99

Copyright Reading Shoulder Unit,
UK

Want Good Results?

- Pick The Right Patients
- (Reject The Wrong Ones)

Red Flags!

- No Clear Bankart Lesion
- Capsular Laxity
- MDI
- Poor Quality Tissues
- Voluntary Dislocators
- Non-Compliant Patients

Ideal Patient????????????

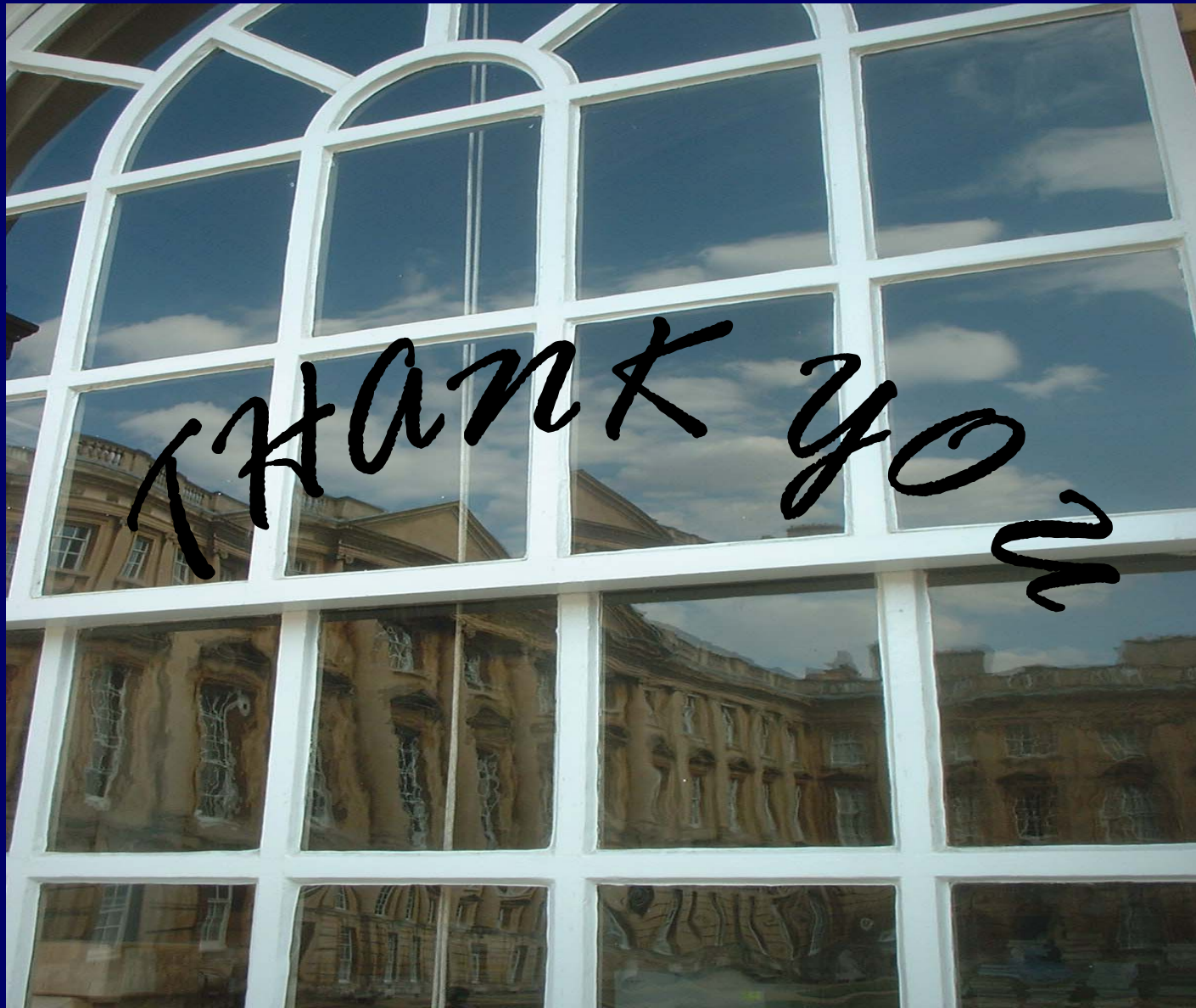
Cole, Warner '00

- Non-Contact Athlete < 30 y/o
- Traumatic Dislocation
- Acute
- Bankart Lesion
- Well-developed IGHL
- Normal Capsule
- Normal Cart.
- Normal Laxity

Ideal Patient

- Well Insured
- Stoic (Farmer).....
-Lives Too Far Away for F/U

If the High Rate of Re-injury and Resultant
Joint Damage and Functional Loss Prompts
Acute Treatment for ACL Rupture, Why
Should Acute Rupture of the IGHL be Any
Different?



Copyright Reading Shoulder Unit,
UK

Alexandra Kirkley et al

- Axial and oblique coronal images using proton density–weighted MRI (TR1000,TE30, with 2 signals averaged) were obtained, and multiplanar gradient recalled acquisition (TR400, TE20; flip angle 20 and 4 signals averaged) was performed. Oblique coronal and axial images were obtained with a section thickness and intersection gap of 5.0 mm and 1.0 mm, respectively.
- Two radiologists with subspecialty interest in musculoskeletal MRI who were blinded to surgical findings independently assessed the MRI results. The radiologists were provided with a clinical history, including the age and gender of the patient and the direction of
- dislocation. Discrepancies in interpretations were settled
- by consensus at an independent meeting with the 2 radiologists.

TABLE 1. *Agreement Between Arthroscopy and Magnetic Resonance Imaging for Pathology of the Shoulder*

Pathology	MRI	Arthroscopy	κ
Hill-Sachs lesion			
Positive	14	14	1
Negative	2	2	
Size			
Small	8	10	0.44
Large	1	4	
SLAP			
N	1	—	
Frayed	—	3	0.6
SLAP	3	4 (Type II)	
Rotor cuff			
N	7 + 2	10	
PT tear	2 + 4	6	0.355
Tendinosis	1	—	
Joint capsule			
N	9	14	
Torn	2	—	0.31
Redundant	3	—	
Bankart lesion			
Positive	13	13	1
Negative	3	3	

MRI indicates magnetic resonance imaging; PT, partial thickness; SLAP, superior labrum anterior to posterior lesion.