

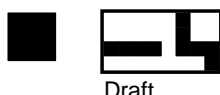

Reading Shoulder Unit



www.readingshoulderunit.com

Centre

RADIOGRAPHIC FOLLOW UP ASSESSMENT FORM FOR VERSO SHOULDER



Draft

HOSP NO:

SHADE CIRCLES LIKE THIS--> ● **STUDY NO:**

HOSPITAL:

SIDE OPERATED: Left Right **GENDER:** Male Female

FOLLOW UP: POSTOP IMM 3 MONTHS 1 YEAR 3 YEARS 6 WEEKS 6 MONTHS OTHER (PLEASE SPECIFY)

YEARS: **MONTHS:**

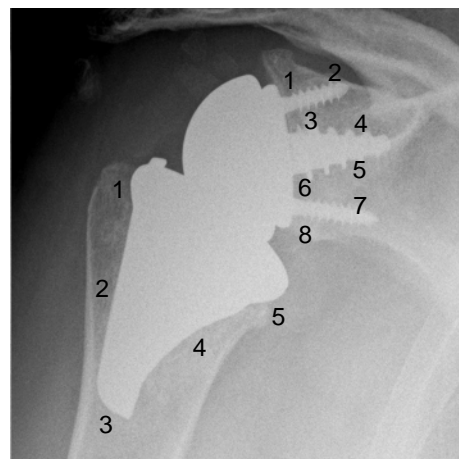
A. No Lucency.
B. Partial Line < 1mm.

C. Progressive Line > 2mm.
D. Prosthesis Displacement (Loosening).

(Loosening)

GLENOID LUCENCIES - Anterior Posterior View:

- Zone 1:** A B C D **Zone 2:** A B C D
Zone 3: A B C D **Zone 4:** A B C D
Zone 5: A B C D **Zone 6:** A B C D
Zone 7: A B C D **Zone 8:** A B C D

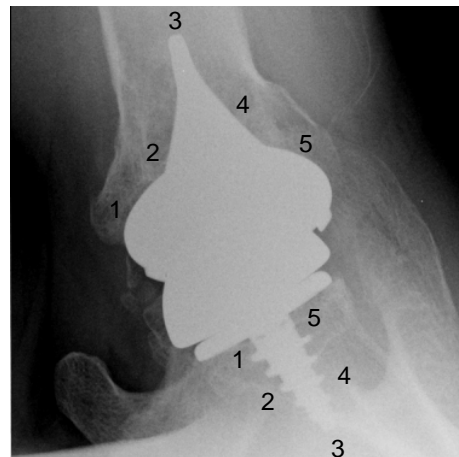


HUMERAL LUCENCIES - Anterior Posterior View:

- Zone 1:** A B C D **Zone 2:** A B C D
Zone 3: A B C D **Zone 4:** A B C D
Zone 5: A B C D

GLENOID LUCENCIES - Axillary View:

- Zone 1:** A B C D **Zone 2:** A B C D
Zone 3: A B C D **Zone 4:** A B C D
Zone 5: A B C D

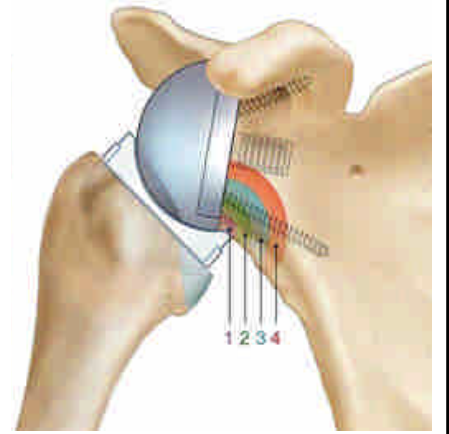


HUMERAL LUCENCIES - Axillary View:

- Zone 1:** A B C D **Zone 2:** A B C D
Zone 3: A B C D **Zone 4:** A B C D
Zone 5: A B C D

**GLENOID NOTCHING DEGREE
(Nerot Grading System for Inferior Scapular)**

- No Notch
- Erosion of Lateral Pillar Only (small notch)
- Erosion of Lateral Pillar with Sclerotic Margins, Indicating Stability
- Erosion Beyond Inferior Screw, Indicating Evolution
- Erosion Under Baseplate as First Sign of Loosening



DATE:

		/			/				
D	D		M	M		Y	Y	Y	Y

Evaluator: _____