

CLINICAL ORTHOPAEDICS AND RELATED RESEARCH  
 Number 368, pp. 80–91  
 © 1999 Lippincott Williams & Wilkins, Inc.

## The Shoulder in Patients With Muscular Dystrophy

*Stephen A. Copeland, FRCS; Ofer Levy, MD; Giles C. Warner, MBBS;  
 and Ron M. Dodenhoff, FRCS*

Shoulder weakness and instability are not usually a major part of the clinical picture of muscular dystrophies. Problems usually do not arise until the patient is wheelchair bound, at which time assistive appliances may be required. The majority of orthopaedic intervention is confined to the rare facioscapulohumeral dystrophy. Facioscapulohumeral dystrophy causes muscular weakness of the face, shoulder girdle, and upper arm with selective sparing of the deltoid muscle. This leads to scapular winging and a marked decrease in flexion and abduction of the shoulder. As the muscles stabilizing the scapula become involved, the scapula starts to wing. The deltoid is spared, but its action is wasted because of the unstable scapula. The deltoid contracts and the arm attempts to move in a normal fashion, but because the scapula is no longer stable, it wings and rotates under the forces of the long lever arm of the upper limb and scapula complex. Mechanical fixation of the scapula to the thoracic wall provides a stable fulcrum on which the deltoid can exert its powerful action on the humerus and abduct the arm without rotation of the scapula. Twenty thoracoscapular fusions were performed on 13 patients. Ten patients (14

shoulders) were available for long term followup. The long term results showed that this operation is successful in achieving stability of the scapula, while greatly improving function and cosmesis. Although the course of this type of muscular dystrophy is variable, the benefits of surgery have not deteriorated with progression of the disease during a maximum followup of 44 years.

The progressive degeneration of skeletal musculature, leading to weakness, atrophy, contracture, and deformity, are the most prominent features of the group of chronic diseases known as muscular dystrophy. The diseases are for the most part hereditary, involving mainly the muscles of the axial skeleton and limb girdles with the primary pathologic changes in the muscle cell itself rather than the nervous system. There are currently more than 10,000 children with muscular dystrophy living in the United States and an estimated 350 per million are born with the disease.<sup>19</sup>

The degree of affliction of the disease on the muscles of the shoulder varies among the different types of disease. In 1868 Duchenne<sup>10</sup> described the clinical course of a progressive muscular atrophy in 13 patients, and his name later became associated with this early onset gender-linked recessive form of muscular dystrophy. Boys born with Duchenne muscular

From the Department of Shoulder Surgery, Royal Berkshire Hospital, Reading, UK.

Reprint requests to Stephen A. Copeland, FRCS, \*Department of Shoulder Surgery, Royal Berkshire Hospital, London Road, Reading, UK, RG1 5AN.

dystrophy often have an entirely normal developmental history until the age of 3 to 5 years, by which time a significant level of muscle bulk has been lost, causing impaired function. The main weakness arises in the lower limb girdle and muscles of the leg resulting in a waddling gait, difficulty ascending stairs, lordosis, progressive equinus, calf hypertrophy, and diminished deep tendon reflexes. Weakness of the shoulder occurs, especially in extension, but this normally does not pose a problem in relation to the other disabilities. By the age of 9 years, progression of the disease prevents independent ambulation in 45% of patients.

Limb girdle dystrophy is confined mainly to the pelvic or shoulder girdle and is found in patients of both genders. It occurs between the first and fourth decades of life, and the progression of the disease is slow with most patients incapacitated within 10 to 20 years of onset.

In 1884 Landouzy and Dejerine<sup>15</sup> reported on a small group of patients in whom the weakness initially was limited to the face and shoulder girdle. This became known as facioscapulohumeral dystrophy and was found to be autosomal dominant with a wide range of expressivity, usually presenting when the patient is between the ages of 15 and 30 years. The muscles commonly involved are the serratus anterior, trapezius, rhomboids, latissimus dorsi, and the muscles around the eyes and mouth. The deltoid invariably is spared. The disease generally runs a benign course, and except when the disease occurs in early childhood, a normal life is probable.<sup>3,4,13,21-23</sup>

## GENERAL TREATMENT

Treatment of the patient with muscular dystrophy is best accomplished by a multidisciplinary team from neurology, genetics, psychiatry, orthopaedic surgery, physical and occupational therapy, and medical sociology. Optimal therapy should be prospective with a thorough approach to total treatment.

Shoulder weakness and instability are not

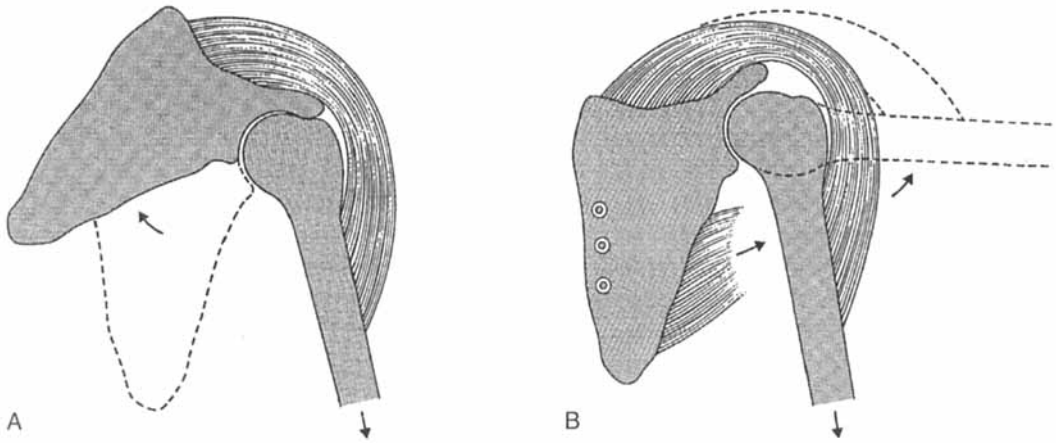
usually a major part of the clinical picture of Duchenne muscular dystrophy or limb girdle dystrophy. Problems normally do not arise until the patient is confined to a wheelchair, at which time assistive appliances can be used. The majority of orthopaedic intervention is confined to the rare facioscapulohumeral dystrophy, in which shoulder weakness occurs early and can interfere significantly with upper extremity function. At an early stage, facioscapulohumeral dystrophy affects tasks of repetitive use requiring abduction and flexion of the shoulder, even in such simple daily activities as overhead dressing.

## TREATMENT OF FACIOSCAPULOHUMERAL DYSTROPHY

The main complaint of patients with facioscapulohumeral dystrophy is the inability to abduct or elevate their arms. Moreover, they fatigue quickly and are unable to hold the arm sustained in abduction and elevation. This is a result of the scapula losing its stable origin and therefore rotating with attempts at abduction; instead of elevating the humerus, the scapula rotates.

As the muscles stabilizing the scapula become involved, the scapula starts to wing. The deltoid is spared but its action is wasted if it does not work from a stable base. The deltoid contracts and the arm attempts to move in the normal fashion, but as the scapula is no longer stable it wings and rotates under the forces of the long lever arm of the upper limb and scapula complex (Fig 1).

Because the deltoid function invariably is spared, mechanical fixation of the scapula to the thoracic wall allows the deltoid to exert its powerful action on the humerus and the patient is able to abduct the arm without the scapula rotating. In effect, anchoring the scapula merely provides a stable fulcrum on which the deltoid can act. Scapulothoracic motion provides  $\frac{1}{3}$  of the movement at the shoulder, the other  $\frac{2}{3}$  being glenohumeral motion. Fixation of the scapula allows a full range of ac-



**Fig 1A–B.** (A) When thoracoscapular muscles are paralyzed, the deltoid loses its stable origin. As the deltoid contracts, the scapula rotates and the arm remains by the side. (B) Fixation of the scapula to the ribs provides a stable fulcrum for the action of the deltoid.

tive abduction at the glenohumeral joint, which normally enables the patient to raise his or her arm above  $90^\circ$  and perform most activities of daily living.

Nonsurgical methods of treatment have been devised, using various orthotic devices to fix the scapula externally against the posterior thoracic cage. However, these were found to be too cumbersome and imposed an additional burden on the already weakened shoulder.

Surgical intervention in patients with facioscapulohumeral dystrophy is split between two schools of thought.<sup>8,9,14,16</sup> Arthrodesis of the scapula to the thoracic wall using screws, wires, or plates, with or without bone graft, produces a solid fusion; however, this is thought to reduce respiratory function and requires a prolonged period of immobilization that may result in muscle atrophy. Scapulo-plexy using less rigid procedures is thought to avoid the problems of reduced respiratory function, and the shoulder can be mobilized almost immediately postoperatively, reducing the risk of muscle atrophy and complications such as stress fractures and nonunion. Unfortunately, the fixation tends to stretch and loosen with time, resulting in an overall less satisfactory outcome.

Several studies have described various techniques for achieving stability of the scapula; unfortunately, they all have been extremely small series with short periods of followup. In 1906 Putti<sup>17</sup> described an interscapular fixation that apparently caused compression of the vessels under the clavicle. In 1964 Rinaldi<sup>18</sup> fixed the scapula to the thorax using a fascial band taken from the fascia lata. This band was passed around the spinous processes of the second, third, fifth, and sixth thoracic vertebrae and then through a hole in the spine of the scapula. This was a modification of the techniques used by Whitman in 1932<sup>24</sup> and Dewar and Harris in 1950<sup>8</sup> who considered it necessary to retain some thoracoscapular movement. Dickson<sup>9</sup> combined scapular axial fascial slings with transposition of the pectoralis major muscle to provide dynamic and static stabilization of the scapula. Although the initial results were satisfactory, the fascial slings stretched and function deteriorated.

To prevent this failure of the fascial slings, Ketenjian<sup>14</sup> described a surgical procedure that would not inhibit extrusion of the ribs during respiration but would provide firm fixation and permit early mobilization. Fascia lata with Mersilene or Dacron strips were passed around the

ribs and through drill holes in the wing of the scapula and tied down snugly with the scapula held in 20 external rotation. Postoperatively, the arm was held in a sling and passive exercises were begun on postoperative Day 2 or 3.

In 1961 Howard<sup>11</sup> published the results of 12 thoracoscaphular fusions done on eight patients. The technique involved firm screw fixation of the scapula to the underlying ribs with tibial strut grafts and additional cancellous bone graft from the proximal tibia. Additional cancellous graft from the posterosuperior iliac crest was added if needed. In 1978, Copeland and Howard<sup>7</sup> described a longterm followup of the patients in whom this procedure was used. The results were encouraging, with all the patients achieving firm fusion between the scapula and the rib cage; in addition, all patients were able to perform sustained maneuvers involving the shoulder. Simple tasks such as getting dressed and cooking were achieved without pausing for rest, which was not possible before surgery. Although fixation of the scapula leaves a considerable scar and a slightly square shouldered appearance, the patients were happy with the overall general improvement in their appearance. Complications included transient pleuritic pain in two patients that resolved within a week. Two patients sustained stress fractures of the ribs that had healed completely by followup. One patient had a nonunion that was treated successfully with iliac crest bone grafting.

In 1973 Bunch<sup>1</sup> described a case of thoracoscaphular fusion in a 17-year-old girl with facioscapulohumeral dystrophy. The technique involved wire loop fixation of the scapula to the third, fourth, and fifth ribs with bone graft laid in between. The patient then had her shoulder immobilized in a shoulder spica cast for 3 months. This resulted in firm fixation and enabled most activities of daily living to be performed. One year later the patient underwent similar surgery on the contralateral shoulder. After the second fusion, the forced vital capacity of that patient had dropped to 74% of the predicted value because of the rigidity of the bilateral fusions. In 1993 Bunch and Siegel<sup>2</sup> reviewed 12 patients (17 shoulders) in whom fu-

sion had been obtained using wire and bone graft. All but one of the patients obtained a solid fusion and had improvement in stability, strength, and range of movement. Complications included a brachial plexus injury, which resolved, and a stiff shoulder. In the same year, Jakab and Gledhill<sup>12</sup> described three patients with four shoulders treated with a similar technique using Luque wires and cancellous bone autograft from the iliac crest to fuse between the scapula to ribs three to seven. Postoperatively, the arm was placed in a sling and active abduction was started 3 weeks later. In 1966 Twyman et al<sup>20</sup> described a similar technique in which the second to sixth ribs were fixed to the scapula with wires. Active exercises were begun on the second day after surgery, and the arm was supported in a broad arm sling for 6 weeks. Although the number of ribs used for fixation was greater than any other technique, this had little effect on the patients' respiratory function and allowed early mobilization in an effort to avoid muscle atrophy.

In 1990 Letournel et al<sup>16</sup> reviewed nine patients, seven of whom had bilateral procedures. The arthrodesis involved a three-plate construct used to fix the scapula to the ribs. The uppermost rib was passed through a window made in the wing of the scapula and then fixed by one of the plates with screws whereas the lower two ribs were fixed to the plates with wires. Patients' shoulders were immobilized for 3 months either in a cast held in abduction or Velpeau sling and swathe bandage. All patients reported an increase in their ability to perform simple tasks of daily living and no patient had winging of the scapula postoperatively. Complications included pneumothorax, pleural effusion, atelectasis, fracture of the scapula, and pseudarthrosis.

### **Indications for treatment**

#### *Power and Winging*

Scapula fusion is indicated for loss of power. Winging of the scapula usually is a painless condition but it may be accompanied by fatigue or aching when attempting prolonged abduction or flexion.

*Cosmesis*

Gross winging of the scapula can be a significant cosmetic deformity. Female patients in particular regard this as their main reason for surgery. In addition, winging may pose problems for routine garment wear. Shoulder straps in clothes tend to slip off the shoulder down the arm.

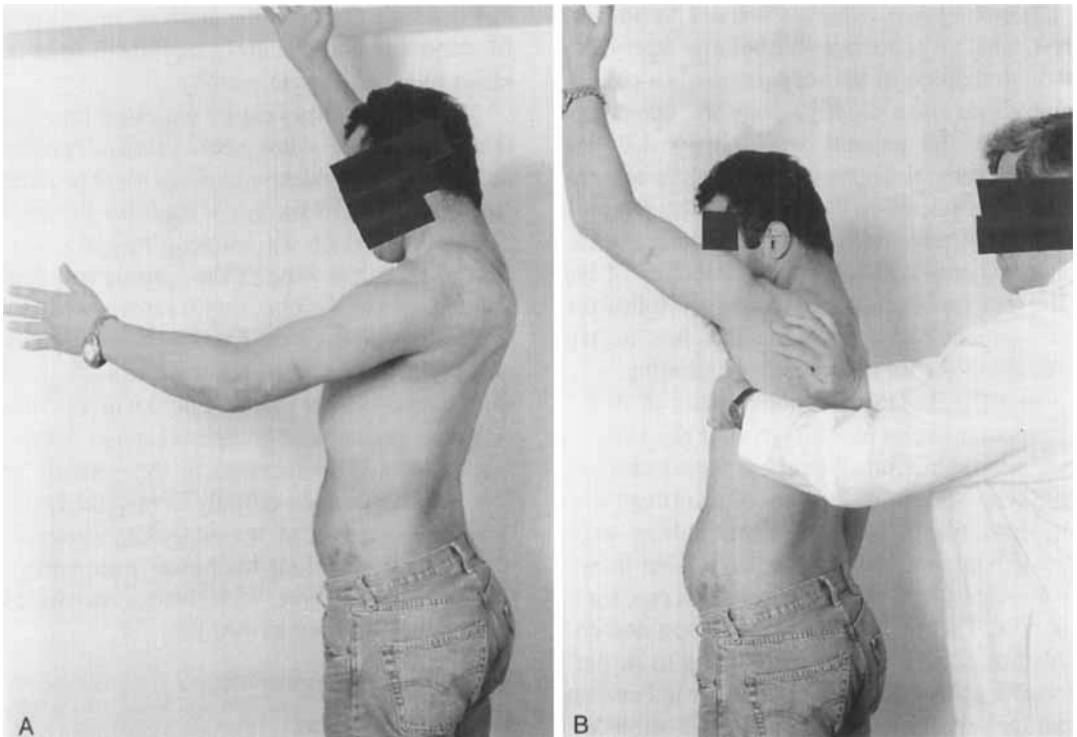
*Loss of Balance of Shoulder*

In a progressive muscular dystrophy, the onset may be asymmetric because the first shoulder may start to wing several years before the other. Patients with this type of muscular dystrophy often feel unbalanced until scapula stability is restored.

*Clinical Evaluation*

Thoracoscapular fusion is a major procedure with numerous inherent risks; therefore, symp-

tom arising from scapular instability must be sufficient to warrant this major intervention. Patients who would benefit from a thoracoscapular fusion can be determined by a relatively simple clinical examination. In 1978, Copeland and Howard<sup>7</sup> described the scapular stabilization test that was designed to assess which patients would be candidates for a thoracoscapular fusion. The test is performed by asking the patient to raise both arms forward and to maintain this position with the arms horizontal, until fatigue causes them to drop to the side. The test then is repeated with the scapula manually held downward and against the chest wall by the examiner to prevent winging. If maintenance of flexion or abduction is found to be improved greatly and the fatigue test is greatly prolonged, then thoracoscapular fusion might be indicated (Fig 2).



**Fig 2A–B.** Scapula stabilizing test. (A) First the patient is asked to raise both arms forward and maintain this position with the arm horizontal until fatigue causes it to drop to the side (Patient had previous fusion on the right side). (B) The test then is repeated with the scapula manually held downward to the chest wall by the examiner to prevent winging. If maintenance of flexion or abduction is found to be easier and the fatigue test is prolonged, a thoracoscapular fusion may be indicated.

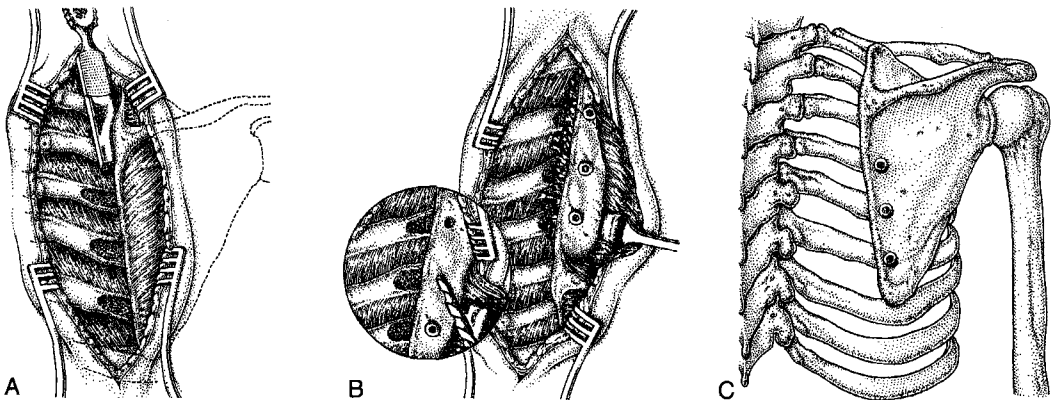
### *Surgical Technique*

The patient lies prone on the operating table with the affected arm hanging over the side of the table. This almost always brings the scapula into the ideal position for fixation to the ribs with the vertebral border lying parallel and 5 to 7 cm lateral to the spinal processes. An incision is made along the medial edge of the scapula. The underlying muscles often are atrophied but occasionally are hypertrophic yet nonfunctioning. The deep surface of the vertebral border of the scapula is denuded of tissue for 2 cm laterally along its entire length, detaching part of the origin of the subscapularis. The superficial medial margin of the scapula is cleared of muscle attachments for 2 cm laterally. Three ribs lying under the most convenient part of the scapula are chosen as the site of fusion, usually the fourth, fifth, and sixth ribs. The periosteum is incised in the line of the rib and then periosteum and parietal pleura are separated on the deep surface of the rib so that a retractor can be placed under the rib to prevent damage to the pleura. The superficial surface of the rib then is petalled with an osteotome and partly decorticated. The scapula is placed in the correct position over the denuded rib and then drilled with the underlying rib drilled with a protective retractor

in place to prevent damaging the pleura (Fig 3). The rib then is tapped, measured for appropriate screw length, and the screw then is tightened loosely. The second and third screws then are inserted in a likewise manner. It is best to drill the second two holes with the first screw in place so that the scapula is fixed during this procedure and the first drill hole is not lost. Cancellous bone chips are harvested from the iliac crest. The screws in the rib are loosened and cancellous bone chips are packed between the rib and the deep surface of the scapula. The screws then are tightened until good fixation of the scapula to the ribs is achieved (Fig 3). The wound is closed over a drain and a shoulder spica cast is applied with the arm at 50° abduction and 30° forward flexion with the hand in front of the mouth. Alternatively, an adjustable brace may be used. Postoperatively, the patient remains predominantly in a sitting position.

### *Postoperative Treatment*

The arm is held in this position with the shoulder spica cast or the adjustable brace. Three months after surgery the arm section of the spica cast is bivalved so the upper section can be removed and the patient can start active abduction. Once control of abduction is re-



**Fig 3A-C.** Operative technique. (A) Decortication of the ribs; (B) Drilling and insertion of rib screws after application of cancellous bone graft and; (C) The final result after tightening of screws.

gained, the rest of the cast is removed. A triangular pillow may be placed under the arm to allow gradual adduction of the arm for 1 week. Physiotherapy is helpful to regain full glenohumeral movement and strengthen the deltoid muscle.

## MATERIALS AND METHODS

Twenty thoracoscapular fusions have been performed in 13 patients. Ten patients (14 shoulders) were available for longterm followup. Three patients were included in the report by Copeland and Howard<sup>7</sup> on thoracoscapular fusion. These three patients had fusions using tibial bone strut grafts fixed with screws, and iliac bone graft placed between the scapula and ribs. The remaining patients have had the modified procedure as described. There were three male patients and seven female patients, with a followup ranging from 1 to 44 years. The three patients with longest followup had undergone bilateral procedures. The age of onset of the disease, date of operation, age at time of surgery, and family history of muscular dystrophy all were recorded. All the patients were seen and examined, and questionnaires were completed regarding their activities of daily living and the progression of their disease. All patients were assessed using the Constant functional score<sup>5</sup> and subjective patient satisfaction score.

## RESULTS

Of the six patients included in the original report by Copeland and Howard,<sup>7</sup> one died in 1992 and the other two were unable to be contacted. The average age of the patients at the onset of symptoms was 13 years, and the average time between onset of symptoms and surgery was 7 years. The average age of the patients at the time of surgery was 21 years (range, 16–35 years) and the average length of followup was 16 years (range, 14 months–44 years). The mean Constant score was 59 points. The average flexion was 123° and average abduction was 103°. Only four shoul-

ders had limitation in external rotation; whereas the average internal rotation was decreased in this group with patients only able to reach their waist with the palm of the affected arm.

Patient 1 had her left shoulder fused in 1954 and her right shoulder fused in 1957. She was the first patient to undergo thoracoscapular fusion using this technique. At followup in 1978 she was reported as having excellent function and range of motion (ROM) in both shoulders. For the first 40 years after the surgery she was able to continue working. However, later progressive wasting in the muscles of her upper arms developed, limiting her mobility until she recently retired from work. She has little problem using a knife and fork, although activities requiring a broader ROM from the shoulder now have become impossible.

Patient 2 had her right shoulder fused in 1956. At followup in 1978 the functional result still was very satisfactory. She was observed to have increasing weakness in her left shoulder at that time, but surgery was not indicated. The weakness now has progressed in the left shoulder and lower limb girdle, which affects her particularly when walking up steps. A radical mastectomy and lymph node dissection on the right side has restricted her ROM additionally. She still was able to use her arm for most activities of daily living despite moderate pain and severely diminished abduction power.

Patient 3 had bilateral fusions in 1977, but his muscular dystrophy had deteriorated by the time of followup to an almost true limb girdle generalized dystrophy. He had maintained good deltoid function and ROM on the right, but some inferior subluxation of the left glenohumeral joint developed because of involvement of the deltoid, which almost universally is spared in this condition. He currently is functioning well as a computer operator.

Patient 4 had bilateral procedures performed 4 years apart. At followup, she was functioning well as a hospital secretary and

was able to perform overhead activities and activities of daily living. She had no pain in either shoulder and there was no evidence of progression of the disease outside the upper limb girdle.

Patient 5 had Duchenne limb girdle type dystrophy. The weakness appeared from infancy and the shoulder manifestation appeared when the patient was in her early teens. She had bilateral procedures performed 4 years apart with an excellent result.

Patient 6 was operated on at age 35 years, and subsequently sustained a fracture of the scapula on postoperative Day 2. She had significant osteoporosis, and it was elected to treat her conservatively with a brace. Ultimately a nonunion developed and she refused additional surgery.

Patients 7, 8, 9 (Fig 4), and 10 were evaluated between 14 and 18 months postoperatively. All four patients were satisfied with their result and were able to obtain greater than 120° flexion and 90° abduction. They all currently are awaiting surgery on the contralateral shoulder.

These results are summarized in Tables 1 and 2.

### Complications

*Early* Two patients of the early series had complaints of pleuritic pain that resolved within a week. A hemothorax developed in one patient requiring drainage in the early postoperative period. Two patients with localized pain in the chest wall while wearing casts later were diagnosed by radiography as having stress fractures of the ribs.

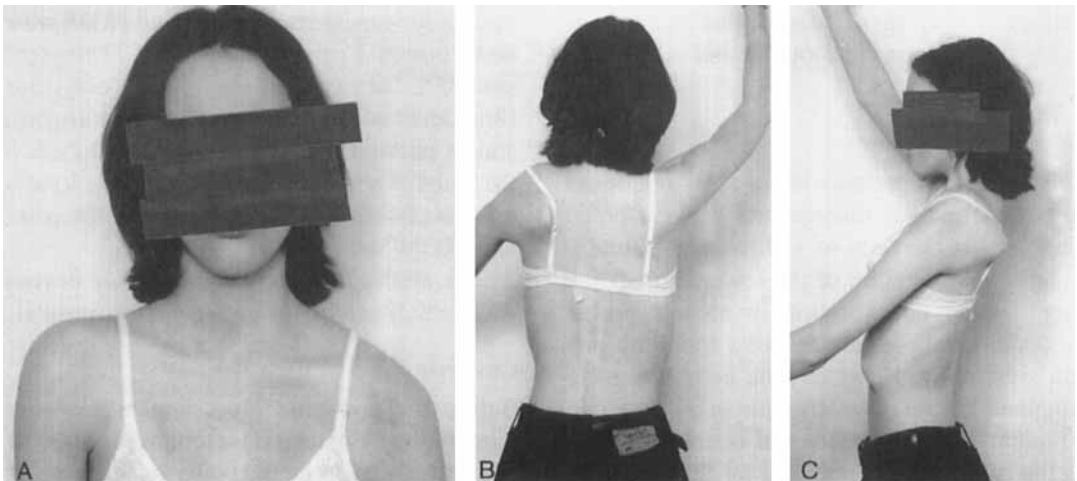
The brace in one patient was not used properly. Subsequently the patient was found to have several screws which had pulled out of the ribs at 3 weeks postoperatively. The fusion was revised using a new plate and larger diameter screws. The patient's shoulder then healed uneventfully.

Another patient sustained a scapula fracture as mentioned previously.

*Late* One patient with a painful nonunion was treated successfully with iliac crest bone grafting. Two additional patients required screw removal because of superficial irritation.

### DISCUSSION

The main complaints before surgery were of weakness of the arm and inability to sustain



**Fig 4A-C.** Photographs of Patient 9 taken 16 months after thoracoscaphular fusion of the right shoulder. (A) Square shouldered appearance on the right side after unilateral thoracoscaphular fusion is evident. (B) Range of movement on the side that was surgically treated is shown. (C) Scapula winging and ROM on contralateral side that was not surgically treated can be seen.



**TABLE 1. Patient Demographics**

Patient Number	Gender	Side	Age at Onset of Symptoms (years)	Date of Operation	Age at Operation (years)	Length of Followup	Family History
1	F	L	9	1954	17	44 years	Y
		R		1957	20	41 years	
2	F	R	14	1956	16	42 years	N
3	M	L	15	1977	22	21 years	Y
		R		1977	22	21 years	
4	F	R	14	1991	21	7 years	N
		L		1995	25	3 years	
5	F	R	5	1989	18	9 years	N
		L		1993	22	5 years	
6	F	R	13	1990	35	1 year	N
7	M	R	15	1997	19	18 months	N
8	F	R	14	1997	19	16 months	N
9	F	R	16	1997	18	15 months	N
10	M	R	16	1997	23	14 months	N

F = female; M = male; Y = yes; N = no.

the arm in the abducted or flexed position, as it would just flop down after a short time (for example, patients complained that they could not reach things in high cupboards nor get books from high shelves). Patients also complained of cosmetic deformity; the scapula would ride up in the neck and wing posteriorly, looking unsightly and causing great difficulty with clothes. Patients also had a dragging sensation in the shoulder and aching and pain after use.

#### *Function and Power*

All three first patients had a slow relentless progress to their disease and were affected severely at the time of followup, eventually having involvement of the lower limb. They had overall deterioration in muscle power and a clinical presentation of a true limb girdle dystrophy. However, the deltoid muscle retained its relative strength in all but one (Patient 3). This patient had inferior subluxation of the glenohumeral joint develop only on his left shoulder because of the exceptionally severe involvement of the deltoid muscle.

All the patients, however, were indepen-

dent, were able to do all daily activities and perform their jobs. (Patient 1 retired recently, more than 40 years after surgery, because of progression of global muscle weakness).

#### *Range of Movements*

The ROM that can be achieved, all of which occurs at the glenohumeral joint alone, is remarkably consistent. The average ROM was: abduction 103°; forward flexion 123°; extension 35°; and external rotation 40° (only four shoulders had limitation of external rotation), and in internal rotation the palm could reach the waist. For all the patients it took at least 6 months after the operation to achieve the maximal ROM and function.

The ability to sustain abduction or flexion was, to the patient, the greatest improvement.

#### *Cosmesis*

Before the operation the scapulae not only wing but are elevated on attempted flexion or abduction, giving an unsightly appearance of widening of the base of the neck. Although fixation of the scapula leaves a considerable scar, the patients were happy to accept this because of the general improvement in appear-

**TABLE 2. Patients' Functional Results: Constant Scores and Range of Motion**

Patient Number	Pain on Scale of 0-15	Activities of Daily Living 0-20				Range of Motion 0-40						Power 0-25 Points (kg)	Total (maximum 100)
		Work or Activities of Daily Living	Sport and Leisure	Sleep	Functional Elevation Level	Forward Flexion	Abduction	External Rotation	Internal Rotation				
1	5	0	0	1	4	4 (90)	2 (50)	0	2	2	—	18	
2	5	0	0	1	4	4 (85)	2 (60)	0	2	2	—	18	
3	15	2	2	1	8	8 (150)	6 (100)	8	4	4	—	44	
4	15	4	4	2	10	4 (90)	6 (100)	10	10	10	10 (5)	75	
5	15	4	4	2	10	10 (150)	10 (150)	10	10	10	9 (4.5)	84	
6	*	4	4	2	10	6 (110)	6 (100)	10	6	6	5 (2.5)	68	
7	11	2	2	*	*	*	*	*	*	*	*	*	
8	10	2	2	2	10	10 (150)	6 (100)	8	6	6	16 (8)	73	
9	15	2	2	1	4	6 (120)	4 (90)	2	4	4	4 (2)	39	
10	15	4	4	1	10	10 (150)	6 (100)	10	8	8	4 (2)	70	
		4	4	1	10	10 (160)	10 (150)	10	6	6	20 (10)	90	

— = unable to perform.

\*Day 2 postoperative fracture of the scapula and pullout of bottom screw occurred. The patient's shoulder was unfused after 10 months of conservative treatment and the patient returned to preoperative activity level.

Patients 1, 2, and 3 were included in the 1978 report by Copeland and Howard.<sup>7</sup>

ance. The position in which the scapulae are fixed gives a maximum range of active movements. This position is farther lateral than the natural position of the scapula and tends to produce a slightly squared shoulder appearance. The patients did not complain about this appearance.

Lung function studies done on some of the earlier patients in series of Copeland and Howard<sup>7</sup> showed only minimal loss of vital capacity. This was confirmed by Bunch<sup>1</sup> who found that the forced vital capacity had dropped to 74% of the predicted value because of the rigidity of the bilateral fusion. Jakab and Gledhill<sup>12</sup> reported diminished vital capacity by an average of 0.213 L after unilateral fusion and an additional decrease of 0.05 L after bilateral fusions. There was no change in forced expiratory volume after unilateral fusion, but after bilateral fusions, a decrease of 0.12 L was seen. Although there are no data concerning respiratory function in the current study, none of the patients complained of shortness of breath or difficulty on inspiration immediately postoperatively or subsequently.

Often it seems that the disease is not symmetric in its onset and only one shoulder may require treatment; several years may elapse before the other shoulder needs surgery. When the disease is asymmetric the patient complains of feeling unbalanced, and this balance is restored by surgery. This complaint may recur later when the other shoulder is affected and again is corrected by thoracoscapular fusion. Eight of 10 patients had or are awaiting thoracoscapular fusion to be done on the remaining shoulder. This shows the success of the operation from the patient's point of view.

Facioscapulohumeral dystrophy is a rare disease, and therefore the operation seldom is required. When it is indicated, the results are very successful, even after long followup, fully justifying the major surgery involved.

## References

1. Bunch WH: Scapulo-thoracic fusion for shoulder stabilization in muscular dystrophy. *Minn Med* 56:391-394, 1973.

2. Bunch WH, Siegal IM: Scapulothoracic arthrodesis in fascioscapulohumeral muscular dystrophy. *J Bone Joint Surg* 75A: 372-376, 1993.
3. Carpenter S, Karpati G: Neuromuscular Pathology. In Carpenter S, Karpati G (eds). *Pathology of Skeletal Muscle*. New York, Churchill Livingstone 507-510, 1984.
4. Chyatte SB, Vignos PJ, Watkins M: Early muscular dystrophy: Differential patterns of weakness in limb-girdle and facioscapulohumeral types. *Arch Phys Med Rehabil* 47:499-503, 1966.
5. Constant C, Murley A: A clinical method of functional assessment of the shoulder. *Clin Orthop* 214:160-164, 1987.
6. Copeland SA: Thoracoscapular Fusion. In Copeland SA (Ed). *Operative Shoulder Surgery*. New York, Churchill Livingstone 297-308, 1995.
7. Copeland SA, Howard RC: Thoracoscapular fusion for facioscapulohumeral dystrophy. *J Bone Joint Surg* 60B:547-551, 1978.
8. Dewar FP, Harris RI: Restoration of function of the shoulder following paralysis of the trapezius by fascial sling fixation and transplantation of the levator scapulae. *Ann Surg* 132:1111-1115, 1950.
9. Dickson FD: Fascial transplants in paralytic and other conditions. *J Bone Joint Surg* 19:405-412, 1937.
10. Duchenne GB: Recherches sur la paralysie musculaire pseudo-hypertrophique ou paralysie myo-sclerosique. *Archives Gen Med* 11 (6 Suppl): 5-25, 179-209, 305-321, 421-431, 552-588, 1868.
11. Howard RC: Thoraco-scapular arthrodesis. *J Bone Joint Surg* 43B:175, 1961. Abstract.
12. Jakab E, Gledhill RB: Simplified technique for scapulocostal fusion in facioscapulohumeral dystrophy. *J Pediatr Orthop* 13:749-751, 1993.
13. Johnson EW, Braddom R: Overwork weakness in FSH dystrophy. *Arch Phys Med Rehabil* 52:333-336, 1971.
14. Ketenjian AY: Scapulocostal stabilization for winging in facioscapulohumeral dystrophy. *J Bone Joint Surg* 60A:476-480, 1978.
15. Landouzy L, Dejerine J: De la myopathie atrophique progressive (myopathie here ditaire, debutant, dans l'enfance, par la face, sans alteration du systeme nerveux). *Rev Med* 5:81-117, 253-266, 1885.
16. Letourmel E, Fardeau M, Lytle JO, Serrault M: Scapulothoracic arthrodesis for patients who have facioscapulohumeral dystrophy. *J Bone Joint Surg* 72A:78-84, 1990.
17. Putti V: L'osteodesi interscapolare in un caso di miopatia atrofica progressiva. *Arch Ortop* 23:319-331, 1906.
18. Rinaldi F: Terapia chirurgica nella forma "facio-scapulo-omeroale" Della distrofia muscolare primitiva. *Clin Ortop* 16:233-243, 1964.
19. Siegel IM: Diagnoses, Management, and Orthopaedic Treatment of Muscular Dystrophy. In Siegel IM (ed). *Muscle and Its Disorders. An Outline Primer of Basic Sciences and Clinical Method*. Chicago, Yearbook Medical 252-254, 1986.
20. Twyman RS, Harper GD, Edgar MA: Thoracoscapular fusion in facioscapulohumeral dystrophy:

- Clinical review of a new surgical method. *J Shoulder Elbow Surg* 5:201–205, 1996.
21. Vinken PJ, Bruyn OW: Fascio-Scapulo-Humeral Dystrophy. *Handbook of Clinical Neurology*. Amsterdam, North-Holland Publishing Company 415–431, 1979.
  22. Walton JN: Muscular Dystrophy and Its Relation to the Other Myopathies. In Adams RD, Eaton LE, Shy GM (eds). *Research Publications*. Vol 38. Association for Research in Nervous and Mental Disease. Baltimore, Williams and Wilkins 398, 1960.
  23. Walton JN, Gardner-Medwig D: Progressive Muscular Dystrophy and the Myotomic Disorders. In Walton JN (ed). *Disorders of Voluntary Muscle*. Ed 4. Edinburgh, Churchill Livingstone 205–237, 1980.
  24. Whitman A: Congenital elevation of the scapula and paralysis of serratus magnus muscle. *JAMA* 99:1332–1334, 1932